

UDC : 616.724-008.6-009.7:612.741.1

## Electromyographic research of muscles functional activity of the maxillofacial area in patients with open bite in different types of facial growth

*Flis P.S. Tsyzh O.O. Kostiuk T.M.*

*Bogomolets National Medical University,  
Kyiv, Ukraine*

**Summary:** This research allowed to trace and analyze changes in the chewing and mimic muscles of patients with open bite according to the type of jaw growth. Chewing and mimic muscles of a child, due to complicated reflex bundles, are precisely the link that first responds to any anatomical and functional changes in the dentognathic apparatus. Electromyographic study of patients at the stages of hardware treatment of open bite pathology allowed making a correlation between the depth of defeat of the neuromuscular complex of the dentognathic apparatus and the clinical manifestations of the disease in patients. he obtained data allowed us to consider the effective and expedient treatment method proposed by us.

**Key Words:** open bite, type of jaw growth, chewing muscles, mimic muscles, electromyography, bioelectric activity, bioelectric rest, surface electrodes, motor point, chewing cycle.

An open bite belongs to the bite anomalies in the vertical plane and represents one of the most severe deformations of the dentognathic area, which is associated with the complexity of orthodontic treatment and the tendency for relapse. [1]. According to foreign and domestic scientific and clinical literature sources on this topic, the frequency

of the spread of open bite is from 0.9% to 20% [2,4,5,6].

The open bite has a polyethiological nature, which is based on both genetic problems and environmental factors that are manifested by dentoalveolar and skeletal changes of the dentognathic apparatus, lead to a disruption of aesthetics, cause severe functional and morphological changes in the masticatory apparatus [7]. The degree of functional impairment is determined by the shape of an open bite, depending on the type of face growth [8, 9].

Number of deformations and anomalies are known to be the result of a violation of the muscles of the maxillofacial area [10]. Violation of the myodynamic equilibrium between muscles by antagonists and synergists is a powerful etiological factor not only for the development of open bite, but also for the cause of relapse of pathology after treatment [11].

Nervous-muscular adaptation of soft tissues after orthodontic treatment does not always reach the norm parameters and can affect the stability of the results [12].

Therefore, in order to achieve the desired results of treatment patients with open bite forms, there is a need for a detailed diagnosis of all forms of open bite taking into account functional and morphological disturbances of the maxillofacial area, which helps to prevent the development of stable deformations of bite and face and develop the most rational methods of treatment and prevention of relapse [13,14].

The most complete understanding of the functional state muscles of the maxillofacial area is given by the method of surface electromyography - a non-invasive painless diagnostic method that we can use in children [15].

**The purpose of this study** is to evaluate the methods of open bite pathology treatment in patients with different types of facial growth by studying and comparative analysis of electromyography data of chewing and mimic muscles in the stages of diagnosis and treatment of this dentognathic anomaly.

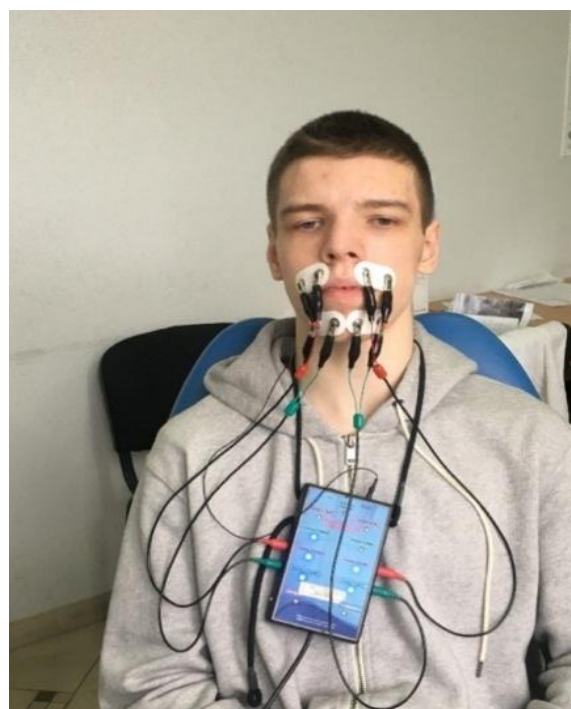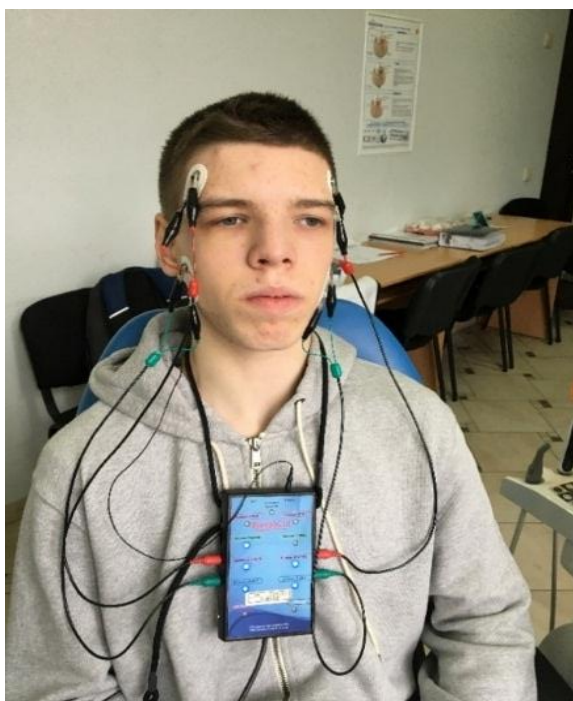
**Material and methods.** During the five years (2014-2018), we conducted the examination and treatment of patients with open bite pathology on the basis of the Department of Orthodontics and prosthodontic propedeutics in the National Medical University named after O.O. Bogomolets. Representative contingent of patients consisted of 36 people (21 girls and 15 boys), age range from 8 to 14 years (Table 1). In general, 94 electromyograms were analyzed at different stages of patient management (36 electromyograms - before orthodontic treatment, 36 electromyograms after the active period of treatment, and 22 electromyograms 12 months after the start of the retention period).

The results were compared with each other and with the results of the age norm [16]. The study of patients with this pathology was performed before the start of orthodontic treatment, after the active period of treatment (12-18 months) and 12 months after the start of the retention period.

All patients were divided into two groups according to the type of growth of the dentognathic apparatus. The first clinical group included patients with a horizontal (or neutral) type of growth (14 people: 9 girls and 5 boys), the second group included patients with a vertical type of growth (22 people - 14 girls and 8 boys).

*Table 1. Number of examined patients.*

Clinical group	General	Sex			
		Female		Male	
		Aбс.	%	Aбс.	%
I	14	9	25	5	14
II	22	14	39	8	22
General	36	23	64	13	36



**Fig.1 The patient's position during the study and location of the electrodes.**

The electromyographic study of the main and auxiliary masticatory muscles, as well as mimic muscles, was performed with the help of the modern computerized eight-channel complex for electromyographic BioEMG III (BioRESEARCH Associates, Inc., USA). An example of the positioning of this diagnostic equipment is shown in Fig. 1. Today it is the only system for electromyography maxillofacial area, which allows to determine the parameters at rest and during compression and chewing in a recording without phase shift. The new BioEMG III modification, according to the characteristics of the manufacturer, exceeds the modification of the previous module in 16 times. Signals in the microvolts are amplified, with almost no noise, in 5000 times according to the original data. The signals are displayed on the display with waveform preservation in a given time interval and displaying averages that give information about the patterns of reduction and relative intensity. The registered signal we saw on the monitor screen in an accessible visualization form: in the form of a graph of the dependence of the pulse rate on the nerve of sensitivity. The system of audio accompaniment of the recorded signal, synchronized with the beam sweep on the screen, allows the physician to see and hear the electrical activity detached from the muscle under investigation. The advantage of this dual control is that minor changes in the amplitude are easier to see on the screen, and the change in frequency is better perceived by hearing [17].

For the study we have chosen the technique of surface functional EMG.

To register bioelectric potentials, we used the standard, single-use, disposable surface bipolar electrodes from BioResearch (ViOFLEX, USA). The electromyographic study of masticatory muscles began with the physical determination of the motor point of the muscle under study. It is a dense formation, for which we ask the patient with the force to squeeze her teeth. The skin in the projection above the engine point was degreased with ethyl alcohol and fixed electrodes having a self-adhesive surface.

The earthing electrode was applied to the patient's right wrists.

The following tests were to be analyzed and studied: the state of patient's muscles rest, free chewing, volitional compression of chewing muscles and prescribed one-sided chewing, swallowing, and free opening of the mouth.

All qualitative and quantitative electromyographic parameters we obtained were analyzed. The data processing was performed using Microsoft® Office® Excel® 2010, Microsoft Corporation (Redmond, WA, USA) and WinPEPI 11.45 programs. The calculation of the parameters of the sampling was carried out in the program WinPEPI 11.45 (J.H. Abramson) module COMPARE2.

**Results and discussion.** We began the electromyographic study of these clinical groups of patients with the study of bioelectric activity of chewing and mimic muscles in a state of relative rest. In norm, the evidence of the absence of pathological changes is the registration of isolines on the monitor. The analysis of the parameters of EMG in patients of the I group did not reveal spontaneous activity in a resting state as evidenced by a direct isoelectric line.

In 4 patients (11%) of the 2nd clinical group, insignificant bioelectric activity was registered in the actual chewing and temporal muscles (1-3 rpm for the actual chewing muscles and 4-6 rpm for the temporal muscles), the magnitude flashes 0,11-0,23  $\mu$ V, which may indicate a compensatory reaction of the maxillofacial area to increase the height of the lower face.

Electromyographic parameters of patients of both groups under study before treatment are presented in Table 2.

In order to evaluate the effectiveness of our orthodontic treatment, we carried out an electromyographic analysis of the chewing and mimic muscles work in the patients of the 1st and 2nd clinical groups after the completion of the orthodontic treatment and 12 months after the beginning of the retention period. The treatment was

carried out by the apparatus we proposed (18) studies are presented in tables 3.4.

The study of the arbitrary chewing of patients of these clinical groups allowed to determine the number of chewing cycles in the patient, to trace the process of changing the sides when chewing, the presence of the dominant side chewing. According to the analysis of random chewing, 12 persons (86%) and the clinical group and 18 (82%) of the second clinical group were found to be disturbed. The fixed asymmetry of the right and left sides is related to the usual one-way chewing.

Electromyographic parameters recorded during swallowing showed no significant functional impairment.

The study of a given one-sided chewing of a patient allowed to trace the functional activity of one individual chewing muscle. A comparative analysis of the results of the examination of the actual masticatory and temporal muscle of patients after the treatment we conducted is presented in tables 3.4. From the analysis of the above data it follows that all, without exception, patients of the studied clinical groups (100%) after the conducted orthodontic treatment, there was a leveling of parameters of muscular activity towards the age-old norm.

The analysis of the parameters of our time "period of silence" has a diagnostic value, since its increase is the initial sign of the violation of the function of reduction of masticatory muscles due to the change of supersegmental inhibitory mechanisms. When analyzing the indicators of the "period of silence" in patients, it should be noted that the time of "silence period" in 2 (14%) patients of the I clinical group, 2 (10%) patients of the II group exceeded the same

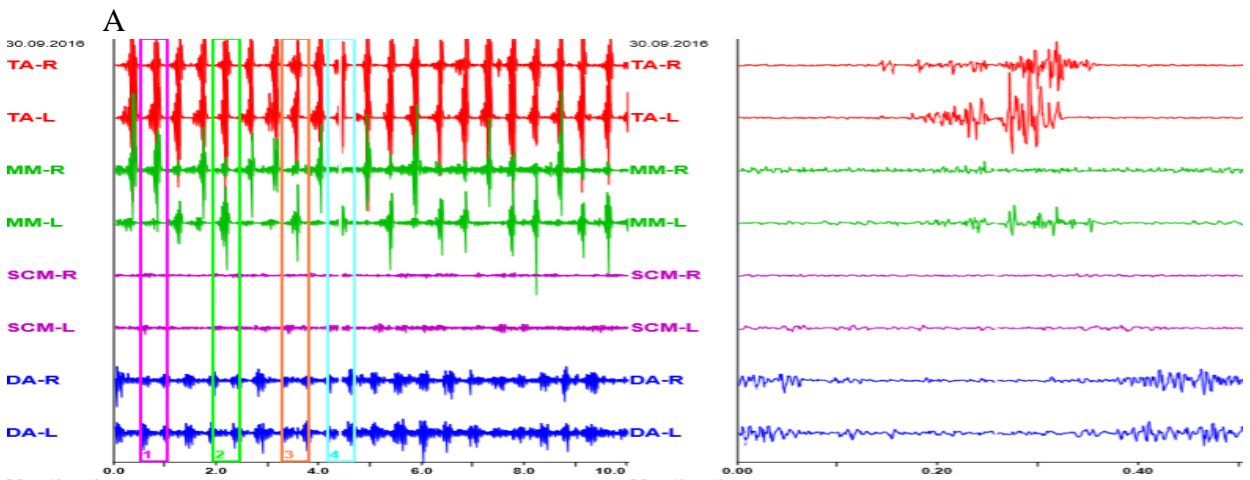
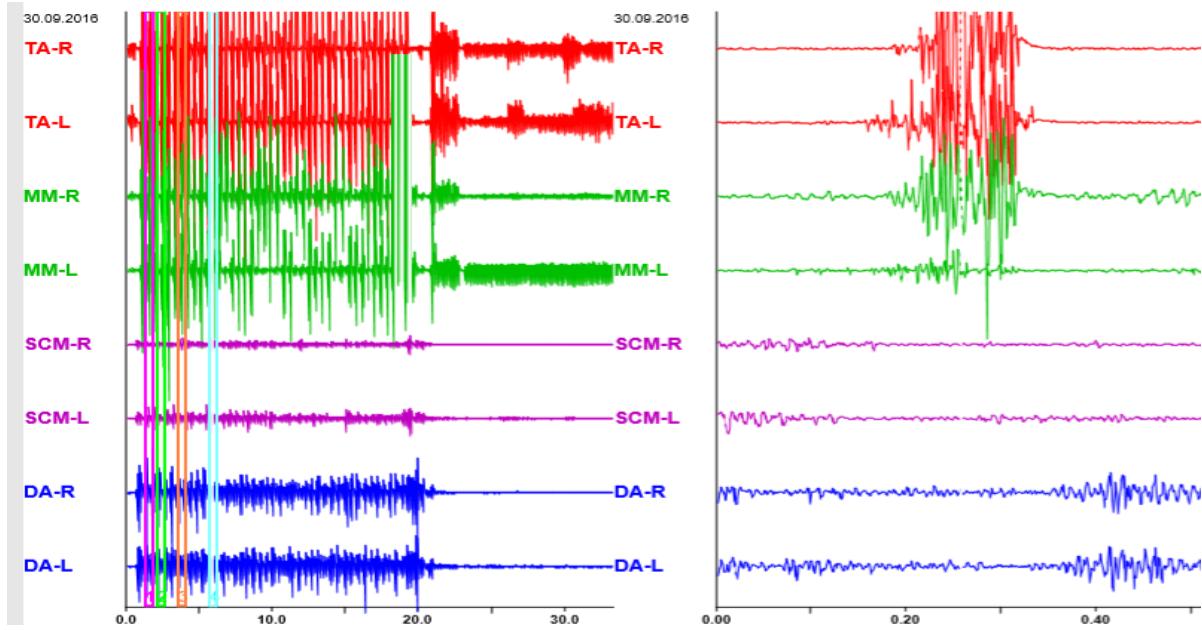
norm of norm. In the remaining patients, the indicated indicator was in line with the normative one. After performed orthodontic treatment, this indicator did not exceed the age-old normative data of any patient. During the retention period, the data remained stable.

An analysis of electromyography data for patients in the I-II clinical group suggests the presence of a mechanism for overloading certain chewing muscles, which is confirmed clinically and due to the bite's appearance. In patients of all studied groups, there were muscle imbalance disorders that manifested themselves as follows: a violation of the ratio of the phases of bioelectric rest and bioelectric activity - in 14 patients (100%) and in the clinical group, in 21 patients (95.5%) in the II clinical group; Inhibition of activity during volitional jaw compression - in 11 patients (78.6%) and in the clinical group, in 9 patients (40.1%) in the II clinical group; violation of the coordinated reflex activity of the masticatory muscles - in 13 patients (93%) and in the clinical group, in 18 patients (81.8%) in the II clinical group.

The determined latency period of the mass reflex of the actual chewing muscle in all patients in our clinical groups was within the range of 6.2 - 6.4 ms, which corresponds to the norm in children. This indicator indicates the preservation of afferent and efferent conductivity and the integrity of the arc of this reflex, both at the level of the brain barium and at the level of the trigeminal nerve.

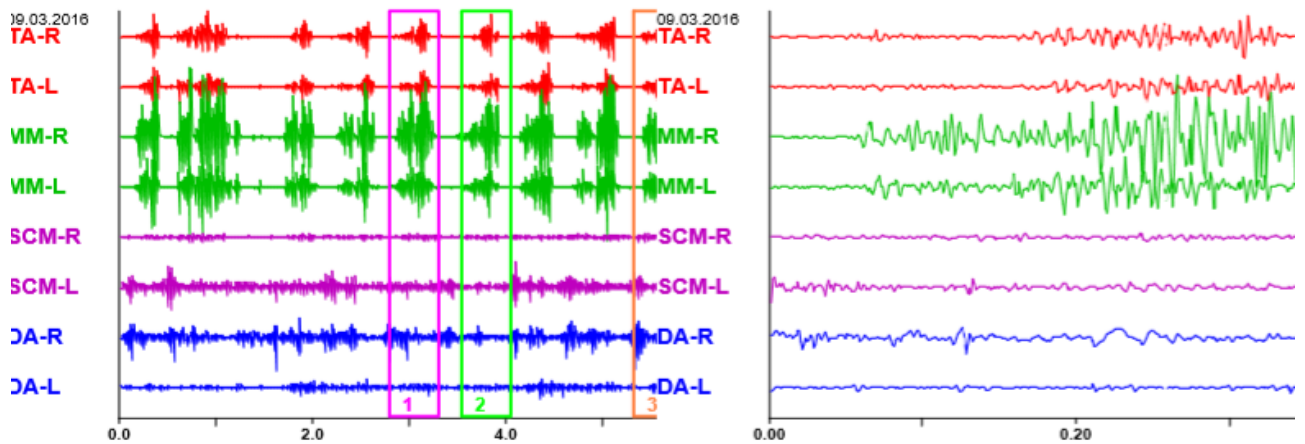
An analysis of the dynamics of our average characteristics of chewing activity during the period of storage in patients is shown in Figure 6.





B

Fig.2 Example 1 electromyogram of patient in clinical group: a full-cycle random chewing, swallowing.



A

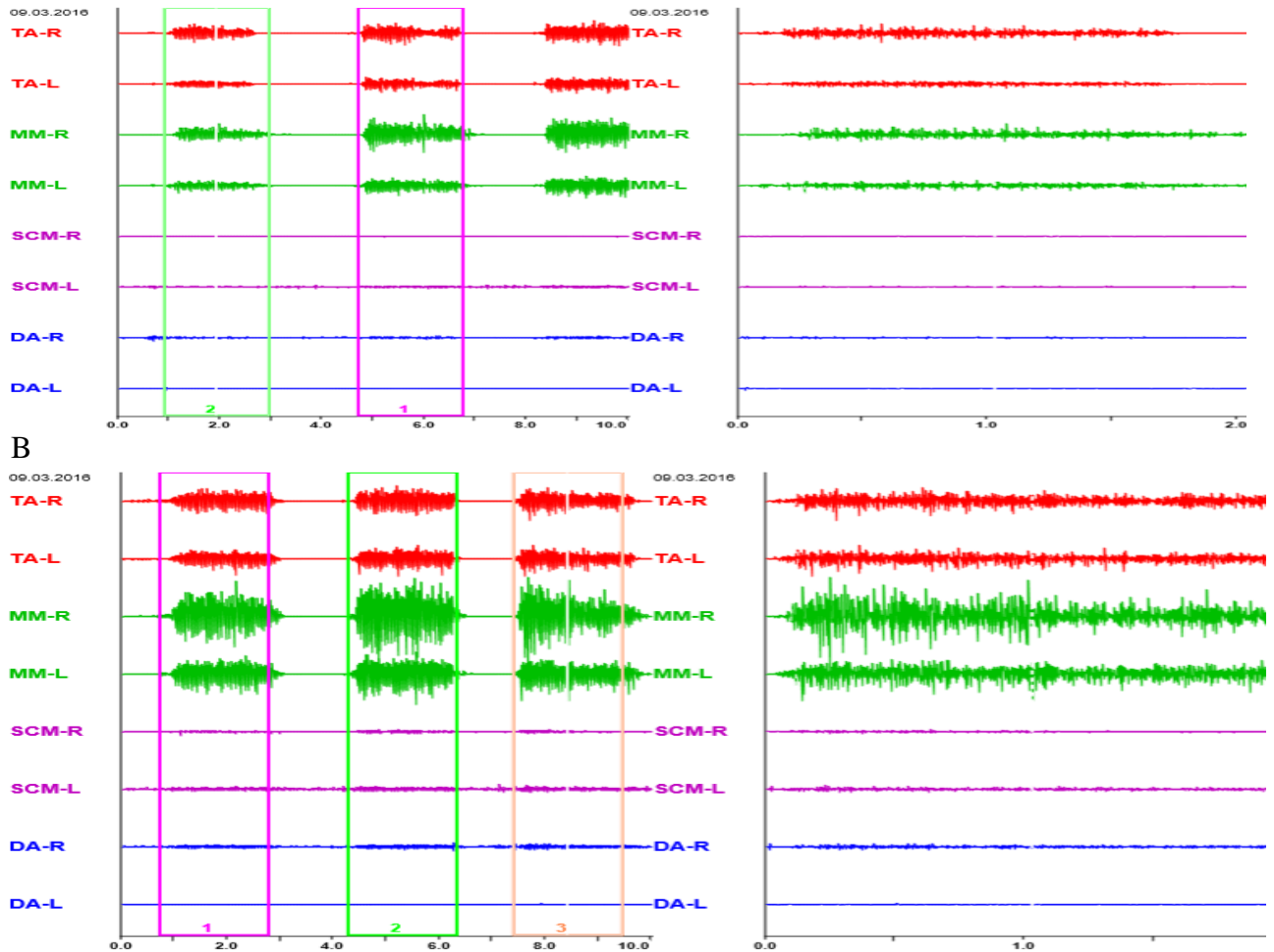


Fig.4 Example of an electromyogram of a patient and a clinical group after treatment of an I group: a complete cycle of chewing and swallowing.

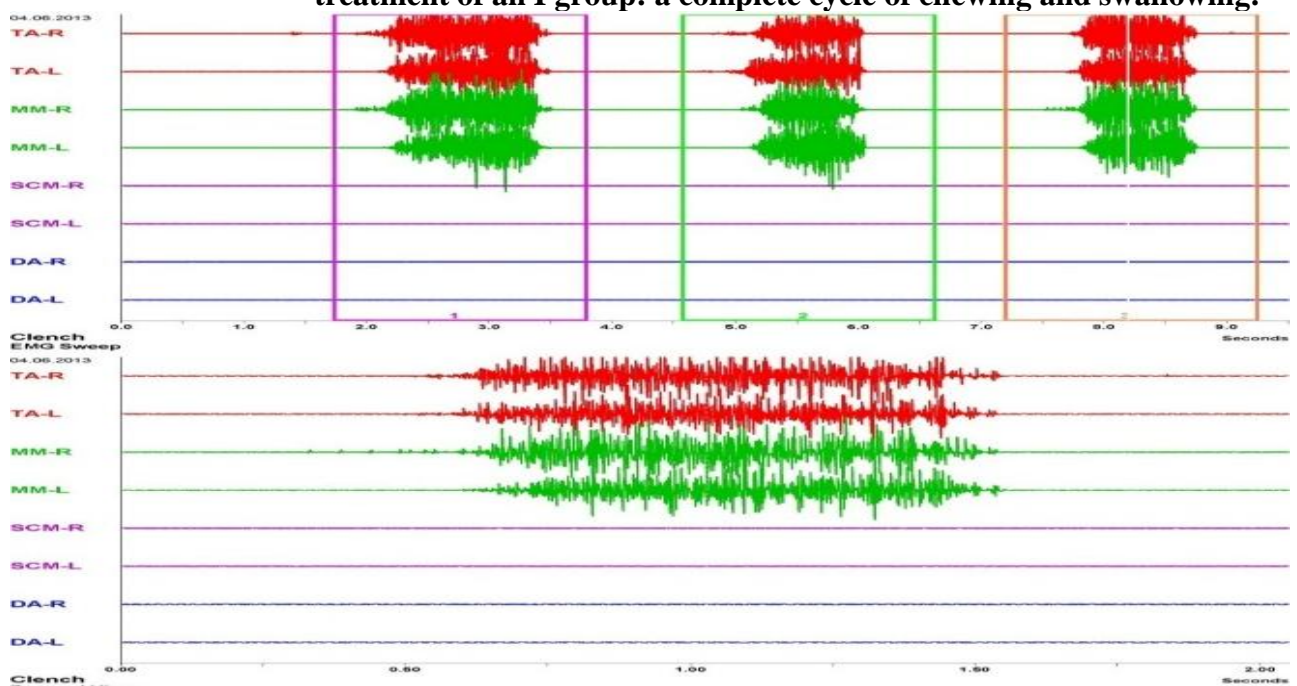


Fig. 5. EMG patients of the clinical group 0 (norms).

**Table 2. EMG parameters of the actual chewing and temporal muscles of patients of the studied clinical groups prior to treatment**

Chewing muscle	Ta, s	Tc, s	k	Ampmax, mV	Amp mean, mV	Tean max	Tean mean
m.masseter dex I group II group	0,361 0,368	0,267 0,256	1,34 1,41	0,72 0,87	0,59 0,62	358,9 364,1	248,4 251,9
m.masseter sin. I group II group	0,362 0,370	0,264 0,255	1,35 1,41	0,78 0,83	0,62 0,70	359,9 365,8	249,9 253,1
m.temporalis dex I group II group	0,346 0,351	0,251 0,244	1,38 1,44	0,91 0,91	0,73 0,78	341,9 359,9	318,9 322,7
m.temporales sin I group II group	0,348 0,357	0,250 0,230	1,39 1,45	0,92 0,95	0,74 0,79	348,8 358,9	319,8 322,9

\*p=+/-0,02

**Table 3. EMG parameters of the actual masticatory and temporal muscles of patients of the studied clinical groups in 12 months after the start of treatment**

Chewing muscle	Ta, s	Tc, s	k	Ampmax, mV	Amp mean, mV	Tean max	Tean mean
m.masseter dex I group II group	0,358 0,361	0,233 0,267	1,3 1,35	0,69 0,72	0,47 0,59	352,7 358,9	247,8 248,4
m.masseter sin. I group II group	0,359 0,362	0,238 0,264	1,32 1,37	0,67 0,78	0,47 0,62	359,2 359,9	249,8 249,9
m.temporalis dex I group II group	0,339 0,346	0,236 0,251	1,31 1,38	0,89 0,91	0,69 0,73	334,2 341,9	310,9 318,9
m.temporales sin I group II group	0,339 0,348	0,239 0,250	1,33 1,39	0,89 0,92	0,69 0,74	329,5 348,8	311,4 319,8

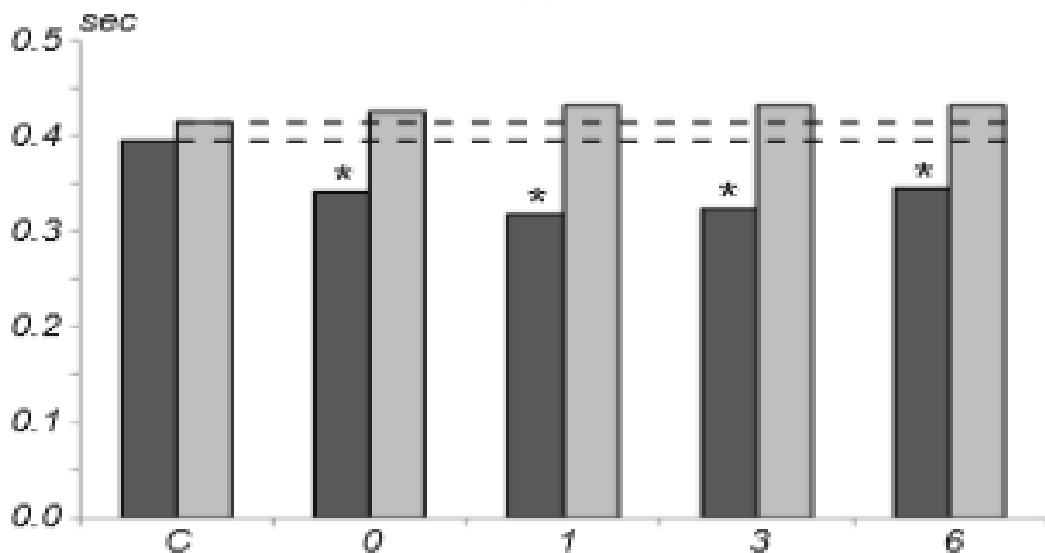
\*p=+/-0,02

**Table 2. EMG parameters of the actual chewing and temporal muscles in patients of the studied clinical groups in 12 months from the beginning of the retention period**

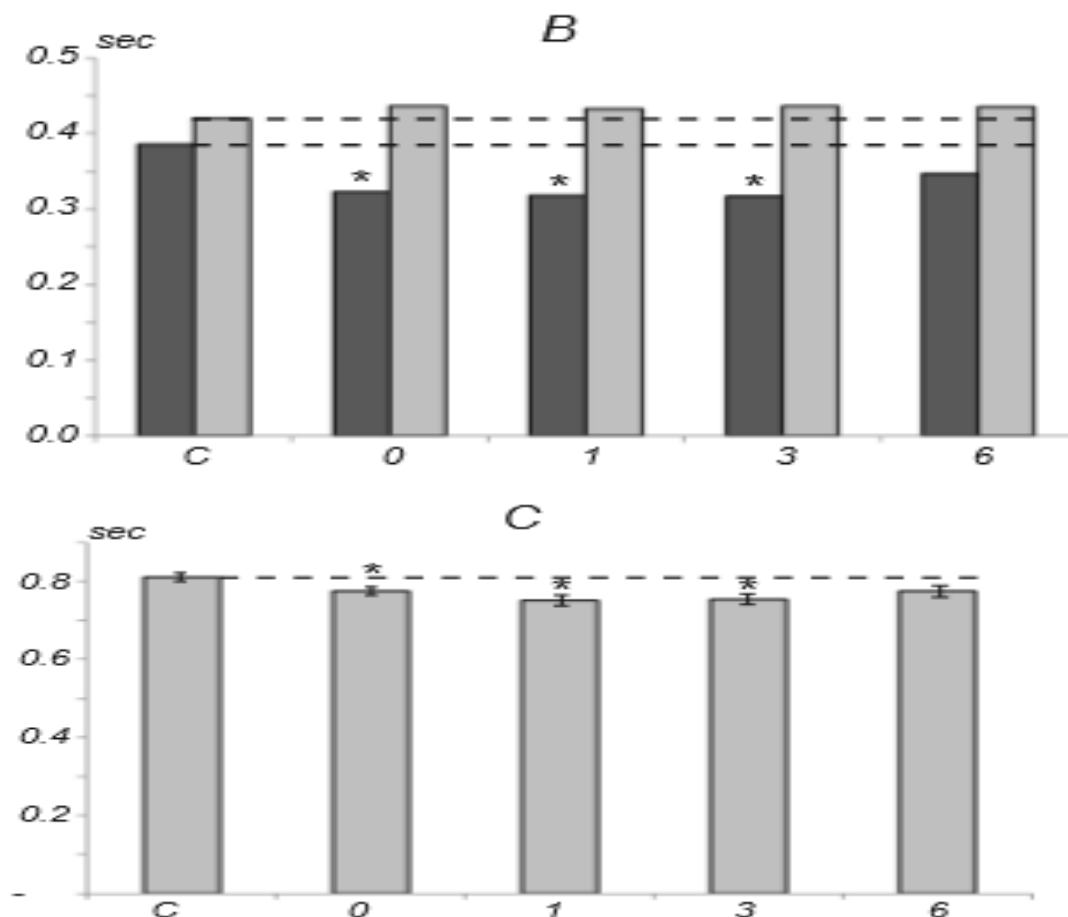
ewing muscle	Ta, s	Tc, s	k	Ampmax, mV	Amp mean, mV	Tean max	Tean mean
m.masseter dex							
I group	0,359	0,231	1,3	0,71	0,49	351,7	246,8
II group	0,361	0,278	1,29	0,72	0,53	351,9	247,4
m.masseter sin.							
I group	0,356	0,244	1,3	0,69	0,55	359,2	249,6
II group	0,360	0,254	1,31	0,72	0,57	359,1	249,9
m.temporalis dex							
I group	0,348	0,241	1,3	0,89	0,68	338,2	317,8
II group	0,347	0,240	1,28	0,91	0,73	341,9	318,9
m.temporales sin							
I group	0,337	0,235	1,29	0,95	0,69	349,1	319,4
II group	0,348	0,250	1,3	0,94	0,71	348,8	319,8

\*p=+/-0,02

**Fig. 6 Dynamics of average time**







characteristics of chewing activity in the retention period. A and B) Structure of active chewing EMG in the actual chewing and temporal muscles, respectively; dark and light columns - duration of activity and phase of silence; the corresponding data are averaged for right and left muscles. C) Average duration of chewing cycle, ms (average data of EMG). C) control group; 0-6) clinical group of patients; 0, 1, 3, and 6 - duration, months, retention period. \*  $P < 0.02$  compared to the normative parameters.

### Conclusions

1. In all patients of our study I and II clinical groups (100%), prior to the onset of the treatment process, were fixed neuromuscular disorders.

2. The complexity of the reflex structure connections of the neuron-muscle component requires a rather prolonged period for its recovery. This is confirmed by the analysis of electromyographic indicators of chewing muscles. Thus, the positive

dynamics of normalization of the main electromyographic indicators is observed after 12 months in 64% of patients, 12 months after the start of the retention period, 94.7% of the initial treatment of the equipment we offer.

3. After 12 months of treatment with an electromyogram, 100% of patients in the I group and 97.3% of the patients in the II group had a resting isolation. In 88.5% of patients in the 2nd clinical group, in case of arbitrary chewing, the alignment of the structure and filling of the chewing gum, normalization of the number of chewing cycles, alignment of the periods of activity and rest of the chewing muscles according to the age norm was observed.

4. 12 months after the beginning of the retention period on an electromyogram, 100% of patients in the II clinical group observed isolation in rest. In 97.9% of patients, at arbitrary chewing, there was a complete alignment of the structure and filling of the chewing gum, the normalization

of the number of chewing cycles, alignment of the relationships of periods of activity and rest of the chewing muscles. All, without exception, patients noticed a lack of discomfort sense.

Taking into account the abovementioned EMG analysis, it should be noted that the use of electromyographic analysis as a control in patients undergoing orthodontic treatment and during the retention period is appropriate and desirable.

Central nervous system through complex reflex bundles, programming the functional activity of chewing muscles, restores its normative balance within 12 months after the end of the period of active hardware treatment. Registration of early manifestations and signs allows to correlate treatment and direct it in a certain direction that greatly enhances the quality of providing orthodontic care.

**Prospects for further research.** In the future, it is planned to deepen the study of the neuromuscular component of the dentognathic apparatus by adding the auxiliary chewing and mimic muscles to the study.

Given the data analyzed by us, it is advisable to carry out an electromyography study of the main and auxiliary masticatory muscles both as an initial diagnosis, and every three months during treatment, and every three months during the retention period: in order to detect changes and adjust the therapeutic measures. Improving the diagnostic algorithm for patients with ocular bite and being treated for the cause of this pathology will allow to analyze the smallest manifestations of neuro-muscular disorders at any stage of treatment, which, of course, will increase the quality of providing dental care to patients.

## REFERENCES

1. Fernando Pedrin Carvalho FerreiraI; Renato Rodrigues de AlmeidaII; Fernando César TorresIII; Renata Rodrigues de Almeida-PedrinIV; Marcio Rodrigues de AlmeidaV; Roberto Santana FilhoVI//Evaluation of the stability of open bite treatment using a removable appliance with palatal crib combined with high-pull chincup//Dental Press J. Orthod. vol.17 no.6 Maringá Nov. /Dec. 2012
2. Безвушко Е.В., Міськів А.Л. Динаміка поширеності зубощелепних аномалій у дітей Львівської області/Вісник проблем біології і медицини.-2015-випуск 2. Том 2(119) с.21-24.
3. Фліс П.С., Філоненко В.В., Дорошенко Н.М. Частота і поширеність аномалій та деформацій зубощелепного апарату в період змінного прикусу// Український стоматологічний альманах.-2016.-№1.-с.75-78.
4. Стороженко К.В. Удосконалення диференційної діагностики прогеничних форм прикусу та прогнозування результатів ортодонтичного лікування у пацієнтів різного віку: автореф. дис. на здобуття наук. ступеня канд. мед. наук: спец 14.01.22 «Стоматологія» / К.В. Стороженко. - Київ, 2017р. – 21с.
5. Pisani L, Systematic review for orthodontic and orthopedic treatments for anterior open bite in the mixed dentition. Bonaccorso L, Fastuca R, Spena R, Lombardo L, Caprioglio A. Prog Orthod. 2016 Dec;17(1):28.
6. Almeida MR, Pereira ALP, Almeida RR, Almeida-Pedrin RR, Silva Filho OG. Prevalence of malocclusion in children aged 7 to 12 years. Dent Press J Orthod. 2011;16:123–131. [[Crossref](#)] [[Google Scholar](#)]
7. Ngan P, Fields HW. Open bite: a review of etiology and management. Pediatr Dent. 1997;19:91–8. [[PubMed](#)]
8. Шпигун М.И., Дмитриенко С.В., Дмитриенко Д.С. Особенности тонуса жевательной мускулатуры у детей с вертикальной резцовою дизокклюзией постоянных

зубов // Сборник научно-практических статей, посвященных 90-летию Волгоградского муниципального здравоохранения /Под ред. В.И. Петрова. – Волгоград; Изд-во ВолГМУ, 2008. – С. 220-222.

9. [Alabdullah M1](#), [Saltaji H2](#), [Abou-Hamed H3](#), [Youssef M4](#).. Association between facial growth pattern and facial muscle activity: A prospective cross-sectional study. [Int Orthod](#). 2015 Jun;13(2):181-94.

10. Макеева И.М. Окклюзия и активность жевательных мышц у здоровых молодых людей / И.М. Макеева., Я.В.Самохлиб // Ортодонтия.-2013.-№1.-С.14-18.

11. Farronato G, Giannini L, Galbiati G, Stabilini SA, Maspero C. Orthodontic-surgical treatment: neuromuscular evaluation in open and deep skeletal bite patients. [Prog Orthod](#). 2013;14:41.

12. Исхакова Г.Р. Особенности функционального состояния жевательных мышц у взрослых пациентов с вертикальной резцовой дизокклюзией/ Г.Р. Исхакова, О.М. Дубова, Л.П Герасимова.- Медицинский вестник Башкортостана.- Уфа.-2013.- Том 8.-№3.- С.88-90.

13. Lentini-Oliveira DA, Carvalho FR, Rodrigues CG, Ye Q, Hu R, Minami-Sugaya H, Carvalho LBF, et al. Orthodontic and orthopaedic treatment for anterior open bite in children. [Cochrane Database Syst Rev](#). 2014;9:CD005515. [[PubMed](#)]

14. Van Dyck C. Dekeyser A. Van Tricht E. Manders E. Goeleven A. Fieuws S. and Willems G. (2016) The effect of orofacial myofunctional treatment in children with anterior open bite and tongue dysfunction: a pilot study. [European Journal of Orthodontics](#). [[PMC free article](#)] [[PubMed](#)]

15. [Woźniak K1](#), [Piątkowska D](#), [Lipski M](#), [Mehar K](#).. Surface electromyography in orthodontics - a literature review. [Med Sci Monit](#). 2013 May 31;19:416-23. doi: 0.12659/MSM.883927

16. Шпак Д.Ю. Особливості лікування гнатичної форми мезіального прикусу у дітей в змінному та постійному періоді прикусу./ Дис. канд наук,2016.- 128с.

17. Kostiuk, T.M., Nespryad'ko, V.P. EMG Activity of the Chewing Muscles during Adaptation of Dental Patients to Fixed Dentures / [Neurophysiology](#). - №3 .-2018. P.43-51

18. Циж О.О., Фліс П.С. Апарат для ретенції результатів лікування відкритого прикусу. Патент на корисну модель №117888 від 10.07.2017р. 5с.